



Pegylated Hyaluronic Acid Dermal Filler Injections in a Patient with Titanium Facial Implants: A Case Report

Dissapong Panithaporn*

The Demis Clinic, Bangkok, Thailand

Abstract

The use of hyaluronic acid-based fillers in correcting facial volume deficits, including the mandibular area, can significantly enhance facial balance and appearance. While this procedure offers undeniable aesthetic benefits, it also carries significant risks, such as contour irregularities, vascular occlusion, and skin necrosis. To increase the safety and precision of volumization in the mandibular area, both the injection technique and the product should be carefully selected. For over three decades, hyaluronic acids (HA) have been used as dermal fillers in minimally invasive cosmetic treatments aimed at facial rejuvenation and sculpting. These injections can serve as an alternative to surgery or complement surgical procedures for patients with facial deformities, trauma, facial disfigurement following tumor resection, or other congenital or acquired conditions.

Keywords: Dermal fillers; PEG; Pegylated hyaluronic acid fillers; Titanium; Facial implant

Introduction

Titanium implants are widely used in medical procedures such as cranioplasty, orbital reconstruction, and mandibular reconstruction [1-3]. This material offers several advantages, including high mechanical strength, corrosion resistance, and a relatively low weight, making it an ideal choice for reconstructive surgeries. However, despite these benefits, titanium implants come with certain disadvantages. Due to their higher thermal conductivity compared to surrounding tissues, implant recipients may experience thermal sensitivity, resulting in an uncomfortable sensation of cold or discomfort in the implanted area [4]. Additionally, titanium implants can sometimes cause allergic reactions, a phenomenon primarily documented with dental implants [5].

Another aesthetic concern with titanium implants is that they can be visible beneath thin skin, particularly in areas like the periorbital region, where the skin is more delicate. This visibility can lead to undesirable aesthetic outcomes, which might be mitigated by the application of dermal fillers to improve contour and disguise the implant beneath the skin.

Hyaluronic Acids (HA) have been used as dermal fillers for over three decades in minimally invasive cosmetic procedures aimed at facial rejuvenation and sculpting [6]. These fillers can be an effective alternative to surgery or used in conjunction with surgical interventions to address facial deformities. HA injections have proven useful in cases of trauma [7-10], facial disfigurement following tumor resection [7,8], and congenital or acquired conditions, such as Parry-Romberg syndrome [11].

However, to date, there are no documented cases of using dermal fillers in patients with facial titanium implants. In this report, we describe the novel application of pegylated HA (PEG-HA) fillers in a patient with titanium facial implants. The cross-linking technology used in PEG-HA, specifically polyethylene glycol diglycidyl ether (PEGDE), demonstrates improved biocompatibility, excellent biointegration, and optimal rheological properties [12]. Additionally, PEG is known for its high safety profile, low toxicity [13], and its ability to reduce immunogenicity and antigenicity [14], making it a promising option for patients with implants.

This case report follows the CARE Guidelines for case reporting [15].

Case Presentation

We present the case of a 28-year-old Thai male, who received titanium implants in the mandible bone, the mandible chin, the maxillary bone and the zygoma bone, seven years before. The patient wished to achieve a more defined and lifted facial appearance. Filler injection with PEG-HA was considered to enhance facial contour tightness. Written informed consent was obtained from the

OPEN ACCESS

*Correspondence:

Dissapong Panithaporn, The Demis Clinic, Unit #SS 6012 - 6013, 388 Rama I Rd, Pathum Wan, Bangkok 10330, Thailand,

E-mail: joedermato@gmail.com

Received Date: 21 Nov 2024

Accepted Date: 13 Dec 2024

Published Date: 16 Dec 2024

Citation:

Dissapong Panithaporn. Pegylated Hyaluronic Acid Dermal Filler Injections in a Patient with Titanium Facial Implants: A Case Report. *Clin Case Rep Int.* 2024; 8: 1718.

Copyright © 2024 Dissapong Panithaporn. This is an open access article distributed under the Creative Commons Attribution License, which permits unrestricted use, distribution, and reproduction in any medium, provided the original work is properly cited.

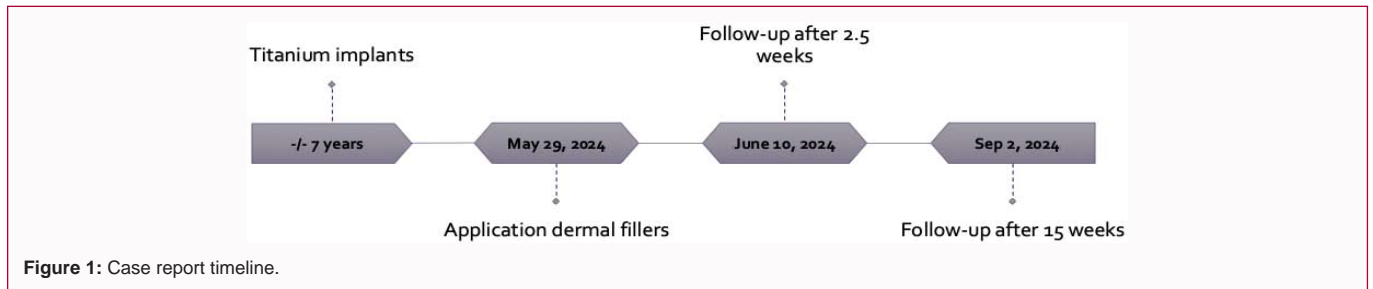


Figure 1: Case report timeline.

patient for publication of this case report and all accompanying images. Ethical approval is not required for this single case report in accordance with local/national guidelines.

A timeline of the process is depicted in Figure 1.

A physical examination showed that the patient was in good general health. Before treatment, photographs were taken of the baseline situation (Figure 2A). Neauvia Intense™ was used in the temporal area (supraperiosteal, 0.5 cc each side, needle size) and the zygomatic suture to lift and support the zygomatic cutaneous ligament (0.3 cc each side). Neauvia Stimulate™ was used along the jawline to create a more defined jawline and face contour on the subcutaneous plane (0.5 cc on each side). Photographs were obtained before and after treatment.

During the first follow-up visit, 2.5 weeks after treatment, the patient reported no adverse events. A new set of photographs was obtained (Figure 2B). As the clinician assessed the results as good but with room for further improvement, touch-up injections were given (Intense™ 1cc, Stimulate™ 2cc).

During the final follow-up visit, fifteen weeks after treatment, the patient reported no adverse events. A new set of photographs was obtained (Figure 2C). The clinician assessed the results as excellent, with no further need for touch-up injections.

Patient Perspective

After I had jaw surgery for my protruding jaw, I noticed that my facial skin started to sag more easily, with more pronounced smile lines and slightly drooping cheeks. This made me feel less confident when taking photos, as I looked older than my age. That's why I decided to undergo this treatment. Before the procedure, I felt excited and anxious because I have sensitive skin. Additionally, when I had jaw surgery, I experienced an infection at the surgical site, which made me very concerned. However, after consulting with the doctor using an X-ray film to locate the position of the titanium plates in my facial bones, we both understood and felt confident. So, I decided to go ahead with the treatment without any worries, and the results were very impressive. Almost no recovery period was needed after the treatment. Everything went well, and I was able to resume my normal activities immediately. There was just a slight bruise on my chin, which faded away after three days.

Discussion

HA fillers have the advantage of a low incidence of adverse events, and their effects can be reversed with the use of hyaluronidase [16]. The fluidity of HA fillers allows for precise injection, making them suitable for both superficial and deep tissue application. In this study, Neauvia Intense and Neauvia Stimulate were used as fillers. The inclusion of two amino acid osmolytes, proline and glycine, in

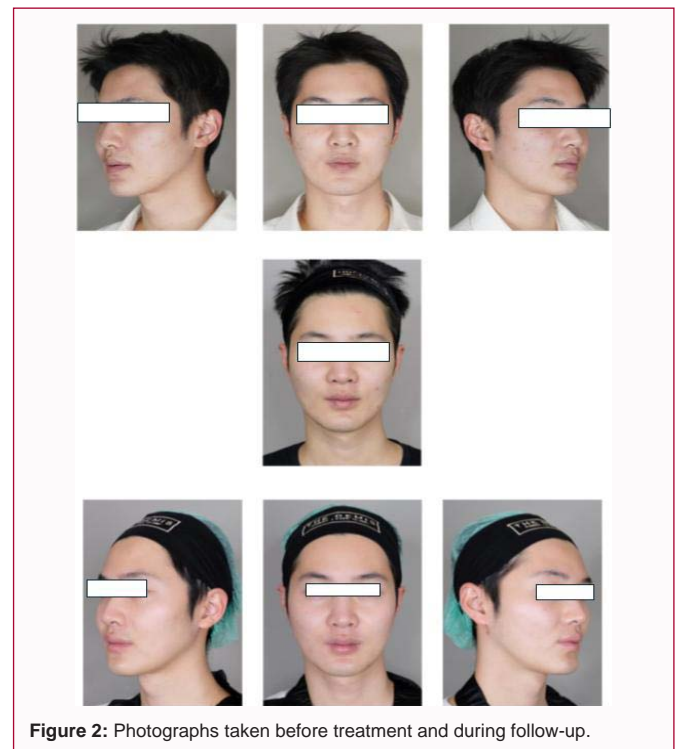


Figure 2: Photographs taken before treatment and during follow-up.

Neauvia's formulation enhances control over the hydrogel's swelling capacity during the post-implant phase [17].

Prospective observational studies have demonstrated the efficacy of PEG-HA fillers in addressing skin irregularities and mid-face volume deficits [18,19]. However, the use of hyaluronic acid fillers is contraindicated in patients with autoimmune diseases, such as systemic lupus erythematosus, rheumatoid arthritis, mixed connective tissue disease, and Hashimoto's thyroiditis [20]. PEGylated hyaluronic acid (PEG-HA) fillers offer additional benefits by reducing immune cell recruitment, the production of reactive oxygen species, and the expression of proinflammatory cytokines, such as tumor necrosis factor- α and interleukin-8 [21].

A prospective study involving 15 patients with Hashimoto's thyroiditis who were treated with PEG-HA fillers reported no immune response, paving the way for their use in patients with titanium facial implants [22]. Although follow-up time remains limited, no adverse events have been observed, and both the physician and the patient were satisfied with the outcome.

In conclusion, this case suggests that PEG-HA fillers can be safely and effectively used in patients with titanium facial implants, offering a promising solution for facial volumization in this patient group.

References

1. Blake GB, MacFarlane MR, Hinton JW. Titanium in reconstructive surgery of the skull and face. *Br J Plast Surg.* 1990;43(5):528-35.
2. Lim HK, Choi YJ, Choi WC, Song IS, Lee UL. Reconstruction of maxillofacial bone defects using patient-specific long-lasting titanium implants. *Sci Rep.* 2022;12(1):7538.
3. Yu Y, Liu W, Chen J, Quan L, Zheng X, Liu L. No Need to Routinely Remove Titanium Implants for Maxillofacial Fractures. *J Oral Maxillofac Surg.* 2019;77(4):783-8.
4. Pan Z, Patil PM. Titanium osteosynthesis hardware in maxillofacial trauma surgery: to remove or remain? A retrospective study. *Eur J Trauma Emerg Surg.* 2014;40(5):587-91.
5. Kim KT, Eo MY, Nguyen TTH, Kim SM. General review of titanium toxicity. *Int J Implant Dent.* 2019;5(1):10.
6. Monheit GD, Coleman KM. Hyaluronic acid fillers. *Dermatol Ther.* 2006;19(3):141-50.
7. Chirico F, Colella G, Cortese A, Bove P, Fragola R, Ruggie L, et al. Non-Surgical Touch-Up with Hyaluronic Acid Fillers Following Facial Reconstructive Surgery. *Appl Sci.* 2021;11(16):7507.
8. Migliardi R, Modugno A, Chirico F, Zerbinati N, Nicoletti GF, Lo Giudice G, et al. Hyaluronic acid injections in post-enucleation or evisceration socket syndrome: a case series. *European J Plast Surg.* 2022;45(2):233-8.
9. Proietti I, Svara F, Battilotti C, Tolino E, Bernardini N, Skroza N, et al. Extreme makeover filler edition: Non-surgical correction for facial deformities post-trauma. *J Cosmet Dermatol.* 2024;23(6):2304-6.
10. Rauso R, Lo Giudice G, Zerbinati N, Tartaro G. Hyaluronic Acid Injections as Nonsurgical Alternative in case of Delayed Diagnosis of Malar Arch Fracture: Case Report and Literature Review. *Case Rep Surg.* 2019;2019:1360741.
11. Clauser LC, Tieghi R, Consorti G. Parry–Romberg syndrome: volumetric regeneration by structural fat grafting technique. *J Craniomaxillofac Surg.* 2010;38(8):605-9.
12. Monticelli D, Martina V, Mocchi R, Rauso R, Zerbinati U, Cipolla G, et al. Chemical Characterization of Hydrogels Cross-linked with Polyethylene Glycol for Soft Tissue Augmentation. *Open Access Maced J Med Sci.* 2019;7(7):1077-81.
13. Fruijtier-Pöloth C. Safety assessment on polyethylene glycols (PEGs) and their derivatives as used in cosmetic products. *Toxicology.* 2005;214(1-2):1-38.
14. Marino F, Cosentino M, Legnaro M, Luini A, Sigova J, Mocchi R, et al. Immune profile of hyaluronic acid hydrogel polyethylene glycol cross-linked: An *in vitro* evaluation in human polymorphonuclear leukocytes. *Dermatol Ther.* 2020;33(3):e13388.
15. Gagnier JJ, Kienle G, Altman DG, Moher D, Sox H, Riley D. The CARE Guidelines: Consensus-based Clinical Case Reporting Guideline Development. *Glob Adv Health Med.* 2013;2(5):38-43.
16. Landau M. Hyaluronidase Caveats in Treating Filler Complications. *Dermatol Surg.* 2015;41 Suppl 1:S347-53.
17. Martina V, Gallo A, Tarantino E, Esposito C, Zerbinati U, Mocchi R, et al. Viscoelastic properties and thermodynamic balance improvement of a hyaluronic acid hydrogel enriched with proline and glycine. *J Biol Regul Homeost Agents.* 2019;33(6):1955-9.
18. Zerbinati N, D'Este E, De Silvestri A, Zullino M, Rabbiosi G, Guida S, Kubik P, et al. Efficacy of Pegylated Hyaluronic Acid Filler Enriched with Calcium Hydroxyapatite: A 24-Week Post-Market, Observational, Prospective, Open-Label, Single-Center Study. *J Funct Biomater.* 2023;14(7):345.
19. Zerbinati N, Płatkowska A, Guida S, Stabile G, Mocchi R, Barlusconi C, et al. Efficacy and Safety of Neauvia Intense in Correcting Moderate-to-Severe Nasolabial Folds: A Post-Market, Prospective, Open-Label, Single-Centre Study. *Clin Cosmet Investig Dermatol.* 2024;17:1351-63.
20. Heydenrych I, Kapoor KM, De Boule K, Goodman G, Swift A, Kumar N, et al. A 10-point plan for avoiding hyaluronic acid dermal filler-related complications during facial aesthetic procedures and algorithms for management. *Clin Cosmet Investig Dermatol.* 2018;11:603-11.
21. Marino F, Cosentino M, Legnaro M, Luini A, Sigova J, Mocchi R, et al. Immune profile of hyaluronic acid hydrogel polyethylene glycol cross-linked: An *in vitro* evaluation in human polymorphonuclear leukocytes. *Dermatol Ther.* 2020;33(3):e13388.
22. Kubik P, Gallo D, Tanda ML, Jankau J, Rauso R, Gruszczyński W, et al. Evaluation of the Safety of Neauvia Stimulate Injectable Product in Patients with Autoimmune Thyroid Diseases Based on Histopathological Examinations and Retrospective Analysis of Medical Records. *Gels.* 2023;9(6):440.