



# Lip augmentation with hyaluronic acid hydrogel cross-linked with polyethylene glycol diglycidyl ether (PEGDE) in two women with autoimmune disease.

## Case report

*Powiększenie ust za pomocą hydrożelu kwasu hialuronowego usieciowanego eterem diglicydylowym glikolu polietylenowego (PEGDE) u dwóch kobiet z chorobą autoimmunologiczną.*  
*Opis przypadku*

### ABSTRACT

Lip augmentation has been one of the most rapidly growing aesthetic procedures since the late 1990s. The trend of lip rejuvenation and correction was popularised and continues to this day.

This study aimed to present the results of lip augmentation using a 24 mg/ml hyaluronic acid hydrogel cross-linked with polyethylene glycol diglycidyl ether (PEGDE) supplemented with l-proline and glycine to reduce post-injection swelling.

The article presents a retrospective study of two women following lip augmentation diagnosed with an autoimmune disease: one with systemic lupus erythematosus and the other with multiple sclerosis. The use of a PEGDE cross-linked hyaluronic acid-based filler gave highly satisfactory results. No adverse events were reported.

**Keywords:** hyaluronic acid fillers, lip augmentation, autoimmune diseases, poly (ethylene glycol) diglycidyl, autoimmunity

### STRESZCZENIE

Od końca lat 90. XX wieku, powiększanie ust stało się jednym z najbardziej dynamicznie rozwijających się zabiegów estetycznych. Trend odmładzania i korekcji ust, który zyskał popularność w tamtych czasach, utrzymuje się do dziś.

Celem pracy było przedstawienie wyników zabiegu powiększania ust za pomocą hydrożelu kwasu hialuronowego o stężeniu 24 mg/ml usieciowanego eterem diglicydylowym glikolu polietylenowego (PEGDE, *polyethylene glycol diglycidyl ether*) uzupełnionego l-proliną i glicyną w celu zmniejszenia obrzęku po iniekcji.

Prezentowano retrospektywne badanie dwóch kobiet, które zostały zdiagnozowane z chorobami autoimmunologicznymi i przeszły zabieg powiększenia ust. U jednej stwierdzono toczeń rumieniowaty układowy, a u drugiej stwardnienie rozsiane. Użycie wypełniacza na bazie usieciowanego kwasu hialuronowego PEGDE dało wysoce satysfakcjonujące wyniki. Nie odnotowano zdarzeń niepożądanych.

**Słowa kluczowe:** wypełniacze z kwasu hialuronowego, powiększanie ust, choroby autoimmunologiczne, poli (glikol etylenowy) diglicydylowy, autoodporność



## INTRODUCTION

Lip augmentation with hyaluronic acid (HA) hydrogel injection is one of the most frequently requested aesthetic procedures in the world [1-3]. There are several reasons for this popularity including the immediate effect, visible improvement of contour and volume, and probably the most important, the safety of the treatment. The immediate effect and the possibility of removing HA with hyaluronidase in the event of an undesirable effect, as well as the requirement for minimal or no recovery period, make the treatment popular in all age groups to increase the natural volume of the lips, correct asymmetry or replenish the volume of the lips lost with age [4, 5].

Currently, there are many types of hyaluronic acid fillers commercially available. They are manufactured using different technologies, have different HA concentrations, may contain various additives and have various rheological properties. These factors influence the clinical effectiveness of the product and are used to adapt HA hydrogels to specific indications [6]. Chemical modifications of HA and their degree, cross-linking technology and the cross-linking agent used, determine the rate of biodegradation and modulate the viscoelastic properties of the final product and its compatibility with various tissues [7, 8].

The lips are part of a very dynamic facial area and the product must be carefully selected so that the treatment gives a natural effect both at rest and during movement. To enhance the lips, hydrogels are usually selected that provide such rheological properties - sufficient elasticity for smoothness and moldability, low water uptake to reduce risk of swelling, and medium to high cohesivity for volumization and projection [7, 8]. When planning the procedure, it is important to take into account the patient's preferences and his or her perception of facial attractiveness, which are not always consistent with the doctor's personal opinion, as well as adapting the product and technique used. An equally important aspect of the procedure is the selection of the appropriate product, and in the presented case it was of key importance, especially considering the diseases diagnosed in the described persons, systemic lupus erythematosus (SLE) and multiple sclerosis (MS).

Injected HA-based soft tissue fillers containing HA or other substances induce an inflow of phagocytic neutrophils and mononuclear cells, stimulating macrophage recruitment and fibroblast activation. This occurs because the immune system is unable to enzymatically break down or phagocytize the injected materials. The inflammatory reaction to fillers with hyaluronic acid, despite the simple composition of these products, is a multi-faceted problem. Each of the ingredients of dermal fillers may influence the induction and development of the inflammatory reaction. Hyaluronic acid itself, although it is a natural and common component

of the body, may have a pro-inflammatory effect [9]. Due to the increased immune response among patients with autoimmune diseases, such treatments using hyaluronic acid-based fillers are contraindicated in this cohort of patients [10]. In the presented work, the commercially available soft tissue HA filler crosslinked with polyethylene glycol (PEG) was used. PEG or PEGDE (polyethylene glycol diglycidyl ether) as a cross-linking agent for the filler with hyaluronic acid has been shown and proven a high safety profile, even when used among autoimmune Hashimoto patients [9]. PEG-crosslinked HA hydrogel has excellent chemical and mechanical properties and high biointegration. PEGDE used as a crosslinking agent seemed to offer considerable advantages in terms of safety and performance of the HA-based filler [11]. Up to date, there have been no reports of granulomas and delayed inflammatory reactions that have been described after the use of PEG cross-linked fillers [12].

Published data suggested that PEGylated HA fillers carry a very low risk of immune-mediated adverse effects. This applies in particular to granulomatous reactions and associated cellulitic processes, and even induces an anti-inflammatory phenotype in immune cells, which may contribute to the beneficial effects of PEG-HA [11, 13].

In this case report, we assessed the safety and efficacy of the procedure using a PEG-crosslinked soft tissue filler among two women suffering from SLE or MS who underwent a lip augmentation procedure.

## METHODS

The two cases were described to show the results of the lip volumization and redefinition using 24 mg/ml HA hydrogel crosslinked with PEGDE (PEGDE-HA 24; Neauvia Intense Lips, Matex Lab S.A., Geneva, Switzerland). The procedures were performed in 2023 by the author in her private clinic. Following the principles of the Helsinki Declaration, both women received written information about the product and procedure, and signed an informed consent form for the procedure and use of their data for scientific purposes.

### Woman 1

A 22-year-old female attended the private practice of the author requesting lip augmentation. She reported that in 2016 she was diagnosed with systemic lupus erythematosus (SLE), and has been under the care of a specialist since then. She had received one previous lip treatment with a 1,4-butanediol-diglycidyl-ether (BDDE)-based HA filler, in 2019, but had been disappointed by the results. At the woman's request, complaints of on and off swelling and lumps, hyaluronidase was used to dissolve BDDE-HA acid on July 3rd 2023. On July 17th 2023 the author proposed lip augmentation with PEGDE-HA hydrogel specifically developed for lip augmentation.

## Woman 2

A 23-year-old female attended the private practice of the author requesting lip augmentation. She reported that in 2021 she was diagnosed with multiple sclerosis (MS) and has been under the care of a specialist since then. She had no previous lip filler treatments done in the past. On August 1<sup>st</sup> 2023 she was proposed a lip augmentation with PEGDE-HA hydrogel specifically developed for lip augmentation.

In both cases, PEGDE-HA was injected in the total amount of 1 ml in two separate treatment sessions:

Woman 1 – first session 0.7 ml, and after 3 weeks 0.3 ml

Woman 2 – first session 0.9 ml, and after 1 week 0.1 ml

To ensure comfort during the procedure, local anaesthesia was used. Both the upper and the lower lip were divided into symmetrical right and left sides by an imaginary vertical line through the centre of the Cupid's bow. The injection points were located 2 mm below the vermillion border of the upper lip and 2 mm above the vermillion border of the lower lip. Using a 27G needle, PEGDE-HA filler was injected into a divided part of the lip. The filler was administered submucosally using a tenting fanning technique. The direction of the needle was changed several times, and filler was placed through these radial lines. Small boluses of 0.05 ml were made at the injection area (Figure 1). The same technique was applied to the other three parts of the lips. Afterwards, a gentle massage of the injected areas was performed to maintain a smooth appearance.

Photographic documentation was done before treatment and 3 or 5 months after the initial injection. After the procedure, both women were advised to avoid make-up, physical exercise and sauna for 48 hours. They also used ice packs to reduce possible swelling.

## RESULTS

Injection volume each time was determined by the physician, but in both cases, volumes did not exceed 1.0 ml for both initial and touch-up treatment combined.

Both women were asked to provide regular feedback to monitor the occurrence of possible complications, side effects and treatment progress. After the first injection, the patients reported that there were no noticeable lumps or bumps and that the lips were neither sensitive nor painful. The shape of the lips was nice, with a clear contour and satisfactory volume. Before the second injection, both noted that their lips healed very quickly, but both felt that more volume was needed. Before and after the treatment photos are shown in figures 2-3.

In the second session, both women had 0.3 ml and 0.1 ml of PEGDE-HA injected respectively. They reported no bruising and no swelling after the second injection. During the follow-up after the second injection, the patients were still very satisfied with the results. No adverse events were observed, either after the first or second injection, and even after that period the aesthetic difference could still be observed (Figure 4-6).

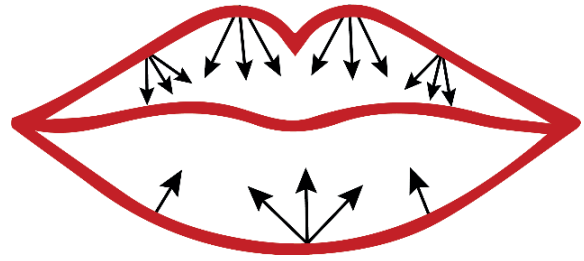


Fig. 1 Injection points for lip augmentation with hyaluronic acid filler Source: Own study

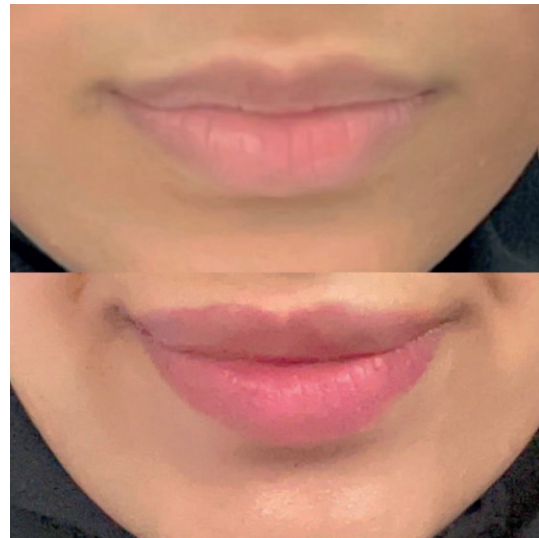

Fig. 2 Woman 1 – before treatment and immediately after the injections of PEGDE-HA for lip augmentation Source: Own study

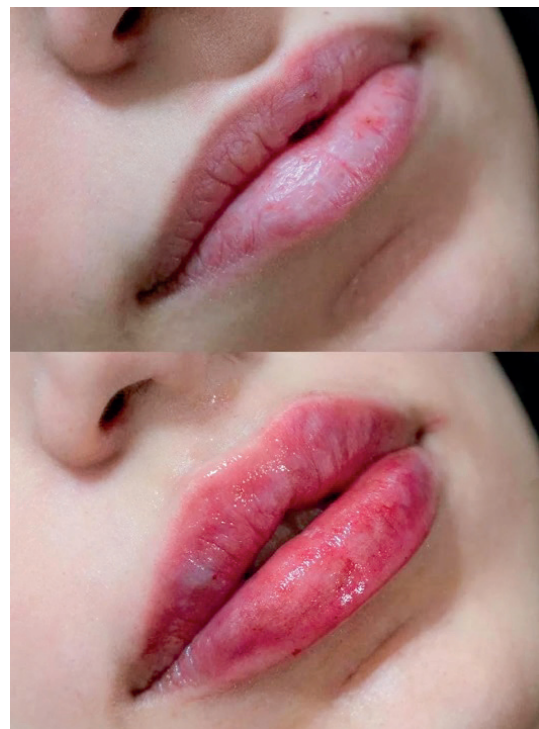
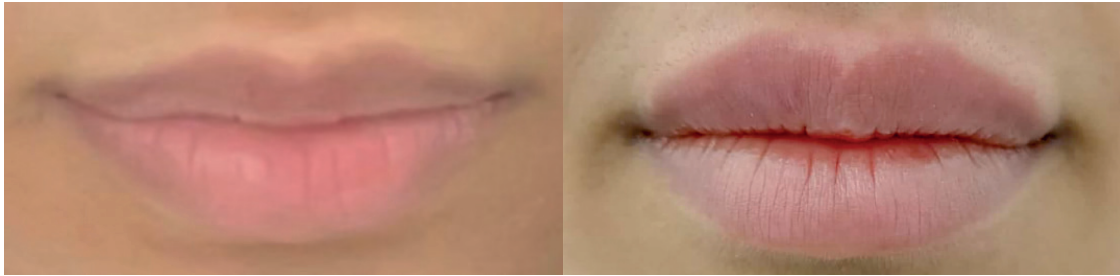
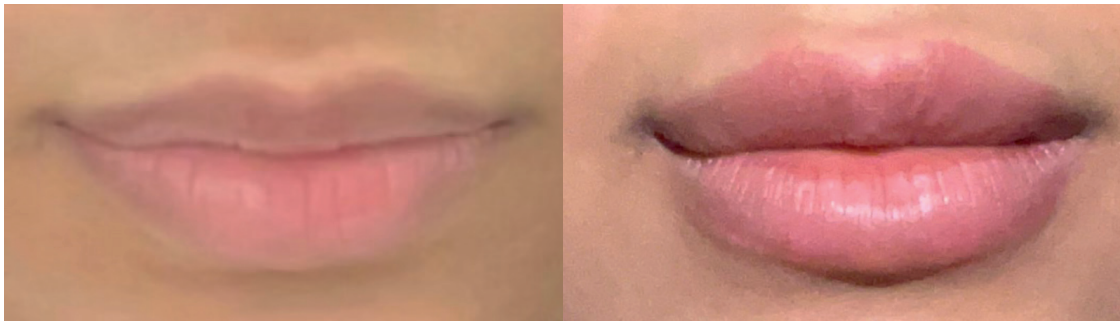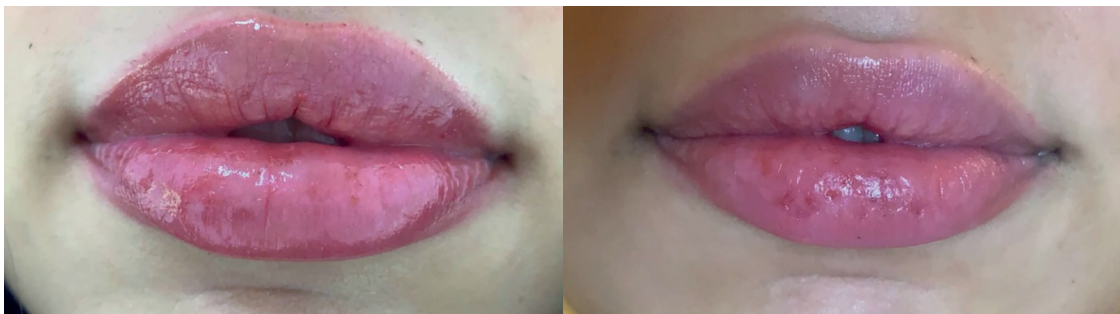
Fig. 3 Woman 2 – before treatment and immediately after the injections of PEGDE-HA for lip augmentation Source: Own study



**Fig. 4** Woman 1 – before and after the second session, 3 weeks after the initial treatment **Source:** Own study



**Fig. 5** Woman 1 – before and 3 months after the initial treatment **Source:** Own study



**Fig. 6** Woman 2 – 50 days and 5 months after the initial treatment **Source:** Own study

## DISCUSSION

In the presented case reports, the PEGDE cross-linked filler used effectively increased the volume of the lips and improved their shape and profile, both in the short term and over time. The effect was assessed positively by both women and doctors. It also seems reasonable to divide the treatment into two subsequent visits, so that the products have time to achieve effects and the body has time to react. This way, more natural-looking results using fewer products could be achieved. This may seem reasonable for all lips, but it was particularly important considering the characteristics of the described women. After the PEGDE-HA injection procedure, both women were very satisfied with the treatment results, describing them as attractive and natural-looking. Importantly, no side effects were reported either immediately after the procedure or in long-term follow-up. Only minimal bruising and swelling were observed, most of which disappeared within 24 hours of injection, which is typical for this type of treatment. Soft tissue

filler cross-linked with PEGDE is a relatively new product in the aesthetic medicine market, with published clinical data just beginning to emerge [12]. Choosing the right product and the technique is the key to achieving the desired and safe results. The choice of HA fillers cross-linked with PEG should be considered safe in the case of patients suffering from autoimmune diseases. Looking at the available publications, a three-year retrospective study of clinical experience with PEGDE-HA for a range of treatment indications demonstrated long-term results without safety concerns, including no nodules, granulomas, or foreign body reactions [12]. PEGDE-HA has been subjected to extensive molecular, chemical, mechanical and histological characterization, but it should be emphasized that few publications shed different light on the use of tissue fillers among patients with autoimmune diseases [9, 12-17]. Clinical results confirm the high safety profile of PEG-cross-linked HA, where, as already mentioned,

no granuloma, foreign body reaction or other complications were detected during the 3-year follow-up period [12]. An additional observation was the use of these preparations in patients diagnosed with Hashimoto's disease. This is another confirmation of the high safety profile and biocompatibility, which was previously demonstrated in histological and in vitro studies published by Kubik et al. [9]. What is important, and what has been emphasized, is that there are no substantive or registration contraindications to the use of fillers with PEGylated HA in patients with Hashimoto's disease. Despite encouraging reports on the safety or trials of using tissue fillers, the assessment of the immunological effect of HA-based hydrogels should always be carefully considered as part of the overall safety assessment of these products. The choice of PEGDE-HA 24 in the described cases was influenced, not only by the high safety profile described in the literature, but also by the fact that it was produced with rheological properties suitable for safe and effective lip enlargement. In the described cases, it was shown that natural-looking results can be obtained with 1 ml of the product, without any observed side effects. It seems reasonable to conduct further observation to examine the effectiveness, safety and durability of the effects of the procedure in various people of different ages. Additional research should focus on the potential mechanisms of PEGylated HA fillers interaction with tissues, free radical/oxidation metabolism, and inflammation.

## CONCLUSIONS

In the presented case report PEGDE-HA was effective for volume augmentation of the lips, and well tolerated with no adverse events reported. Natural results were achieved even with a small amount of filler used, and both subject and doctor satisfaction was high. The choice of HA fillers cross-linked with PEG should be considered safe in the case of women suffering from SLE and MS. Of course, extreme caution should always be exercised when offering treatment to patients suffering from autoimmune diseases, and followed by manufacturers' recommendations. Evaluation of the performance and use of HA soft tissue fillers in patients suffering from autoimmune diseases should be carefully considered as part of the overall safety assessment of these products. However, the first reports on the use of PEGylated HA among patients suffering from Hashimoto's disease [9] are optimistic, although of course, it should still be the subject of further observations.

## REFERENCES / LITERATURA

1. Sarnoff DS, Gotkin RH. Six steps to the "perfect" lip. *J Drugs Dermatol*. 2012;11(9):1081-1088.
2. International Society of Aesthetic Plastic Surgeons (ISAPS). ISAPS international survey on aesthetic/cosmetic procedures performed in 2021. [https://www.isaps.org/media/vdpdanke/isaps-global-survey\\_2021.pdf](https://www.isaps.org/media/vdpdanke/isaps-global-survey_2021.pdf). Accessed 02.01.2024.
3. American Society of Plastic Surgeons (ASAPS). Plastic surgery statistics report 2020. <https://www.plasticsurgery.org/documents/News/Statistics/2020/plastic-surgery-statistics-full-report-2020.pdf>. Accessed 03.01.2024.
4. De Boule K, Glogau R, Kono T, et al. A review of the metabolism of 1,4-butanediol diglycidyl ether-crosslinked hyaluronic acid dermal fillers. *Dermatol Surg*. 2013;39(12):1758-1766. <https://doi.org/10.1111/dsu.12301>
5. Greene RM. Comparing the use of injectable fillers for the youthful lip and the more mature lip. *Facial Plast Surg*. 2019;35(2):134-139.
6. Gavard Molliard S, Albert S, Mondon K. Key importance of compression properties in the biophysical characteristics of hyaluronic acid soft-tissue fillers. *J Mech Behav Biomed Mater*. 2016;61:290-298. <https://doi.org/10.1016/j.jmbm.2016.04.001>
7. de la Guardia C, Virno A, Musumeci M, et al. Rheologic and physicochemical characteristics of hyaluronic acid fillers: overview and relationship to product performance. *Facial Plast Surg*. 2022;38(2):116-123. <https://doi.org/10.1055/s-0041-1741560>
8. Monticelli D, Martina V, Mocchi R, et al. Chemical characterization of hydrogels crosslinked with polyethylene glycol for soft tissue augmentation. *Open Access Maced J Med Sci*. 2019;7(7):1077-1081.
9. Kubik P, Gallo D, Tanda ML, et al. Evaluation of the Safety of Neauvia Stimulate Injectable Product in Patients with Autoimmune Thyroid Diseases Based on Histopathological Examinations and Retrospective Analysis of Medical Records. *Gels*. 2023;9(6):440. <https://doi.org/10.3390/gels9060440>
10. Heydenrych I, Kapoor KM, De Boule K, et al. A 10-point plan for avoiding hyaluronic acid dermal filler-related complications during facial aesthetic procedures and algorithms for management. *Clin Cosmet Investig Dermatol*. 2018;11:603-611. <https://doi.org/10.2147/CCID.S180904>
11. Zerbinati N, Esposito C, Cipolla G, et al. Chemical and mechanical characterization of hyaluronic acid hydrogel cross-linked with polyethylene glycol and its use in dermatology. *Dermatol Ther*. 2020;33(4):e13747. <https://doi.org/10.1111/dth.13747>
12. Rauso R, Nicoletti GF, Bove P, et al. Clinical Experience with PEGylated Hyaluronic Acid Fillers: A 3-year Retrospective Study. *Open Access Maced J Med Sci*. 2021;9(B):1168-1173. <https://doi.org/10.3889/oamjms.2021.6457>
13. Marino F, Cosentino M, Legnaro M, et al. Immune profile of hyaluronic acid hydrogel polyethylene glycol crosslinked: An in vitro evaluation in human polymorphonuclear leukocytes. *Dermatol Ther*. 2020;33(3):e13388. <https://doi.org/10.1111/dth.13388>
14. Zerbinati N, D'Este E, Farina A, et al. Morphological evidence following pegylated filler treatment in human skin. *J Biol Regul Homeost Agents*. 2017;31(2):79-85.
15. Martina V, Gallo A, Tarantino E, et al. Viscoelastic properties and thermodynamic balance improvement of a hyaluronic acid hydrogel enriched with proline and glycine. *J Biol Regul Homeost Agents*. 2019;33(6):1955-1959.
16. Zerbinati N, Mocchi R, Galadari H, et al. In Vitro Evaluation of the Biological Availability of Hyaluronic Acid Polyethylene Glycols-Cross-Linked Hydrogels to Bovine Testes Hyaluronidase. *Biomed Res Int*. 2019;3196723. <https://doi.org/10.1155/2019/3196723>
17. Zerbinati N, Sommatis S, Maccario C, et al. Toward physicochemical and rheological characterization of different injectable hyaluronic acid dermal fillers cross-linked with polyethylene glycol diglycidyl ether. *Polymers (Basel)*. 2021;13(6):948. <https://doi.org/10.3390/polym13060948>

otrzymano / received: 24.01.2024 | poprawiono / corrected: 06.02/2024 | zaakceptowano / accepted: 15.02.2024